



RADIOTHERAPY OF LIVER CANCER : IMPROVEMENTS DUE TO BREATHING CONTROL



Robin Garcia, Laurent Mineur, Véronique Bodez, Nathalie Gaillot-Petit

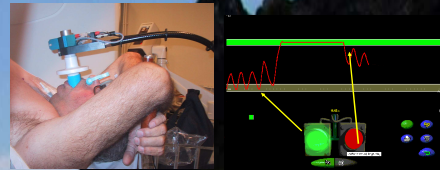
Institut Sainte Catherine - AVIGNON France r.garcia@isc84.org

INTRODUCTION :


X-Ray visualization of liver movements show displacements of 1 cm to 4 cm during free breathing. No focused radiotherapy can be possible including so important margins. To get an acceptable precision, a breathing control is necessary. The improvements need to be evaluated by measuring the setup error of daily sessions.

MATERIAL ET METHODS :

The patients got the benefit of a personalized alpha cradle immobilization. Moderate Deep Inspiration Breath Hold (MDIBH) was applied using the SDX₂/Dyn'R spirometer. This equipment has been built to be specific to the radiotherapy domain. It is able to measure a respiratory signal without any drift even in an apnoea phase.



Three set-up evaluations were conducted using orthogonal portal images matched with their corresponding DRR. A retrospective evaluation on 194 images was followed by a prospective evaluation on 101 images to highlight the influence of a new positioning method. We didn't ask the patient to move in the head-feet direction to avoid any stretch which would make the positioning more complex. When it was needed, we favored a limited table displacement. A last evaluation on 244 images was justified to display the real treatment conditions.



RESULTS :

The following results are presented using two standard deviation which cover 95% of all events.

2σ

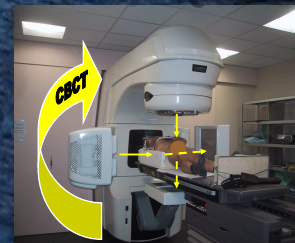	R-L bonny marks	A-P bonny marks	H-F bonny marks	H-F diaphragme matching
1	0,88 cm	0,70 cm	1,07 cm	1,72 cm
2	0,74 cm	0,50 cm	1,05 cm	1,15 cm
3	0,83 cm	0,71 cm	0,95 cm	1,29 cm

Anterior-Posterior images were used to evaluate Right-Left directions on bony marks and Head-Feet directions on cupola matching. Lateral images were used to evaluate Anterior-Posterior and Head-Feet directions on bony marks.

DISCUSSION:

Deep Inspiration Breath Hold avoids the supra-centimetric errors. The method modification consisting of no patient movement inside his immobilization device involved a reduction in H-F error. The problem is specific to the abdominal area because H-F displacements of the patient can involve a variation of the vertebral curve.

The third evaluation showed daily reality.



CONCLUSION :

External immobilization and MDIBH helped to reach a sufficient precision to treat liver cancers in a curative objective. 52 treatments were, so delivered applying the technique without any methodological difficulty. The set-up error evaluations show clearly the high difficulty to obtain an important accuracy in abdominal irradiations. The last improvements should be done with current IGRT implementations and the use of implanted markers.